

Bone Dysmorphia-Induced Blindness Following a Secondary Hyperparathyroidism: A Case Report

Gael Honal Mahoungou^{1,2*}, Daniel Tony Eyeni Sinomono^{1,2}, Ghislain Armel Mpandzou¹, Regis Franck Moyikoua¹, Josue Euberma Diatewa¹, Dinah Happhia Motoula¹, Benedicte Diatewa¹, Helena Botokoto Bothard¹, Richard Loumingou^{1,2}

¹Faculty of Health Sciences of Brazzaville, Marien Ngouabi University, Brazzaville, Republic of Congo

²Department of Nephrology, University Hospital of Brazzaville, Brazzaville, Republic of Congo

Email: *mahoungouael@yahoo.fr

How to cite this paper: Mahoungou, G.H., Sinomono, D.T.E., Mpandzou, G.A., Moyikoua, R.F., Diatewa, J.E., Motoula, D.H., Diatewa, B., Bothard, H.B. and Loumingou, R. (2021) Bone Dysmorphia-Induced Blindness Following a Secondary Hyperparathyroidism: A Case Report. *Open Journal of Nephrology*, **11**, 489-494.

<https://doi.org/10.4236/ojneph.2021.114041>

Received: November 3, 2021

Accepted: December 18, 2021

Published: December 21, 2021

Copyright © 2021 by author(s) and Scientific Research Publishing Inc.

This work is licensed under the Creative Commons Attribution International License (CC BY 4.0).

<http://creativecommons.org/licenses/by/4.0/>



Open Access

Abstract

Introduction: Conjunctival-corneal or choroidal calcifications are frequent in SHPT, blindness is however exceptional. We report a case of blindness secondary to compressive ischemic optic neuropathy. **Case Report:** Mr. B.E.K., 49 years old, has a chronic renal failure secondary to unlabeled glomerular nephropathy for 17 years. He has been on chronic hemodialysis for 12 years and has had SHPT for nine years. He secondarily developed disabling segmental osteoarticular deformities associated with kyphoscoliosis, “drumstick” fingers and facial dysmorphism. Five months before admission he developed eye pain and reduced visual acuity progressing within one month to blindness. Biology noted: serum creatinine at 726 $\mu\text{mol/l}$ (60 - 120 $\mu\text{mol/L}$), azotemia at 14.3 mmol/l (2.5 - 7.5 mmol/L), serum calcium at 2.25 (2.25 - 2.55 mmol/L), phosphatemia at 1.13 (0.8 - 1.35 mmol/L), alkaline phosphatases at 2196 (5 - 270 IU/L) and parathyroid hormone level at 2257 (10 - 60 pg/mL). Retinal angiography revealed lesions suggestive of ischemic neuropathy. The orbit CT scan with 3D coronal reconstruction revealed narrowing of the caliber of the optical channels with dystrophic thickening of the skull base and cranial vault. Cranioencephalic and orbital MRI revealed diffuse brown tumors and pre-chiasmatic optic atrophy. **Discussion:** The most frequent ocular complications of SHPT are conjunctival-corneal or sclero-choroidal calcifications, asymptomatic, associated with hypercalcemia. Compressive manifestations are rarer, represented mainly by an amputation of the visual field, diplopia, ptosis or blindness, as described in our patient. The main cause is osteodystrophy and brown tumors of the skull base (1% - 2%). **Conclusion:** This case report underlines the importance of early detec-

tion of SHPT, in order to avoid its major complications, such as blindness, especially since current preventive and curative measures have proven their effectiveness.

Keywords

Blindness, Secondary Hyperparathyroidism, Bone Dysmorphism

1. Introduction

Secondary hyperparathyroidism (SHPT) is a common complication of chronic kidney disease, usually caused by abnormal phosphocalcic metabolism. Prolonged dialysis causes the development of CKD-mineral and bone disorder (CKD-MBD) [1] [2] [3] responsible for musculoskeletal lesions of various locations, especially brown tumors (1.5% to 1.7%). The localization of these lesions at the orbital level, with blindness as a complication, is exceptional [4] [5] [6]. We report a case of blindness after ischemic optic neuropathy by orbital compression.

2. Case Report

We report a case of a 49-year-old patient with a history of chronic renal failure (CRF) for 17 years secondary to unlabeled nephropathy, on hemodialysis for 12 years.

He has no history of diabetes or old high blood pressure. He was operated on for appendicitis when he was 20 years old. He has regular dialysis, 3 sessions per week and for a duration of four hours each on a left humeral arteriovenous fistula. The calcium in the dialysate is 1.75 mmol/l. The phosphocalcic balance at the initiation of dialysis notes a parathyroid hormone (PTH) level of 137 pg/ml (normal value: 10 - 60 pg/ml), serum calcium: 1.73 mmol/l, phosphoremia of 2.28 mmol/l. The concentration of 25-OH-vitamin D is 16 ng/ml (normal value: 20 - 50 ng/ml). Clinically, the arterial pressure is balanced under antihypertensive treatment, the average interdialytic weight gain is 1.5 Kg with a dry weight of 60 Kg. The mean dialysis dose (Kt/v) is greater than or equal to 1.2.

Eight years after dialysis, segmental and axial osteoarticular deformities and pathological fractures of the limbs gradually occur. Biology shows an increased PTH level up to 1341 ng/ml, calcium level at 2.18 mmol/l, phosphoremia at 1.91 mmol/l, 25-OH vitamin D of 32 ng/ml. Standard radiographs show diffuse bone demineralization. Non-compliance with its treatment with calcium carbonate and alfacalcidol was observed. Calcimimetics were not available. The rate of biological monitoring was irregular.

Five months prior to admission, he presented with eye pain with reduced visual acuity, which was symmetrical and gradually worsening; having progressed to blindness after one month. Clinical examination on admission revealed dis-

abling axial and segmental osteoarticular deformities with kyphoscoliosis, “drumstick” fingers and facial dysmorphism; bilateral blindness with optic atrophy in the fundus; there were no other signs of neurological focus or cardiorespiratory disorders. A picture of optic neuropathy associated with a generalized dysmorphic syndrome on SHPT was captured.

The biological examinations confirmed the diagnosis of SHPT secondary to CKD with serum creatinine at 726 $\mu\text{mol/l}$ (60 - 120 $\mu\text{mol/l}$), blood urea at 14.3 mmol/l (2.5 - 7.5 mmol/l), with calcemia at 2.25 (2.25 - 2.55 mmol/l), hyperphosphatemia at 1.13 (0.8 - 1.35 mmol/l), alkaline phosphatases (PAL) at 2196 (5 - 270 IU/l) and especially an increase in parathyroid hormone (PTH) to 2257 (10 - 60 pg/ml). Secondly, imaging was performed, including an orbit CT scan with 3D coronal reconstruction which showed narrowing of the caliber of the optical channels with dystrophic thickening of the cranial base and vault (**Figure 1**).

In addition, a cranioencephalic and orbital MRI made it possible to highlight diffuse brown tumors of the cranial vault with a thickening of the skull bases and a pre-chiasmatic optic atrophy (**Figure 2**).

Retinal angiography revealed lesions suggestive of compressive ischemic optic neuropathy (**Figure 3**). From those findings we retained the diagnosis of blindness due to ischemic optic neuropathy, secondary to CKD-MBD, compressive of the optical channels.

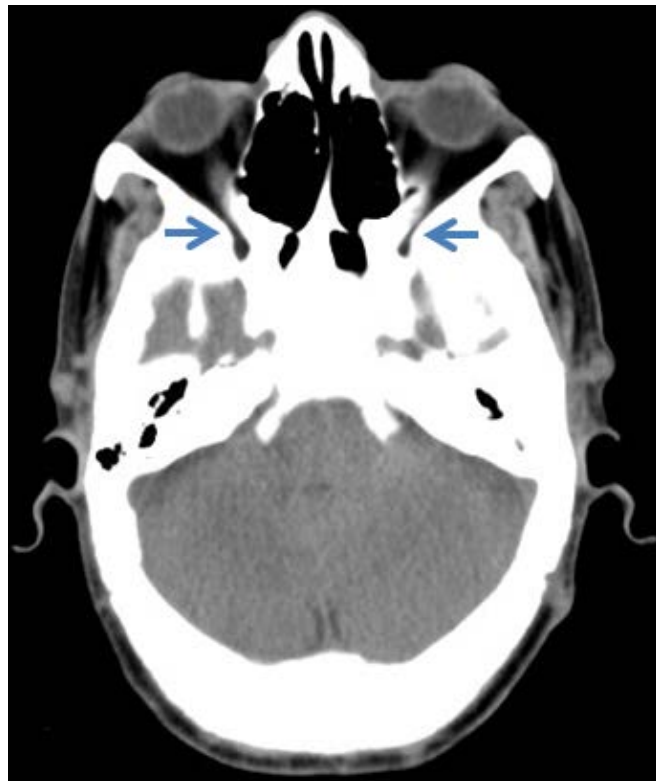

Figure 1. Cerebral orbital CT scan in axial section showing a narrowing of the caliber of the optical channels (blue arrows).

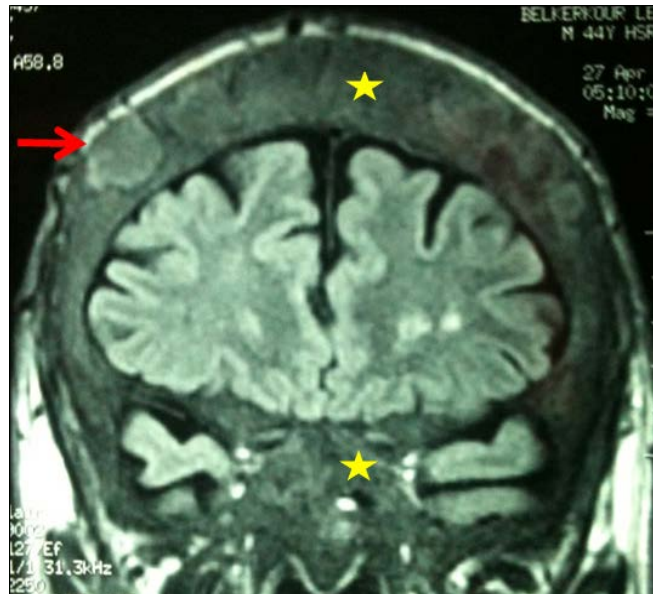


Figure 2. Cranioencephalic and orbital MRI in coronal section (Flair sequence) showing a brown tumor of the vault of the skull (red arrow) and thickening of the diploe and the base of the skull (yellow star).

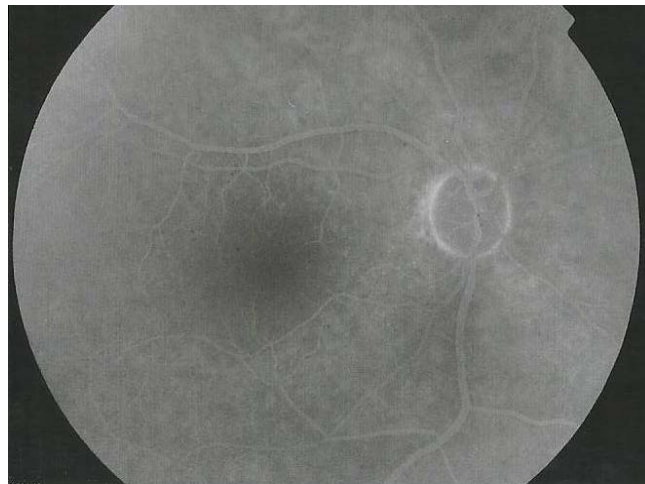


Figure 3. Retinal angiography showing an absence of papillary opacification and a scarcity of capillaries (bilateral lesions).

3. Discussion

Secondary hyperparathyroidism (SHPT) is a complication of CKD [1] [2] [3] Its diagnosis is clinical, radiological and laboratory [1] [7]. CRF is responsible for a disturbance of phosphocalcic metabolism with phosphorus retention, lack of calcitriol synthesis, hypocalcemia, then secondarily an increase in ALP and PTH by parathyroid hyperplasia [8] [9] [10] Prolonged dialysis causes the development of CKD-MBD which includes a set of musculoskeletal abnormalities including SHPT (bone resorption, brown tumors and periosteal reaction), osteosclerosis, osteoporosis, osteomalacia, and calcifications of soft and vascular tis-

sues [2] [3] [10].

Our patient presented with a complicated CKD from SHPT by CKD-MBD. He presents with osteoarticular deformities, pathological fractures and facial dysmorphism. These manifestations have been reported by other authors and are thought to be due to CKD-MBD [1] [3] [8] [9] [10]. Other manifestations have also been reported, such as bone and joint pain, pruritus [1] [3].

The main sites of localization are: ribs, clavicle, sternum, pelvis, femur, and rarely vertebrae, skull and face. The bone resorption predominantly in the phalanges is pathognomonic [4] [8] [9]. The main radiological signs include resorption of the phalangeal tufts (92.9%), thinning of the cortices (85.7%) and osteosclerosis (87.1%) [3].

Our patient also presents bilateral blindness, which represents the peculiarity of our observation. Indeed: Orbito-ocular involvement is a rare complication of CKD-MBD, with only a few reported cases [2] [5] [6] [11]. The most frequently reported manifestations are conjunctival, corneal (band keratitis) and sclero-choroidal calcifications, generally benign, diagnosed by CT scan [2] [3] [7] [10] [12] [13] [14].

Compressive manifestations are rarer, mainly represented by headaches, edema and ophthalmological symptoms (visual field amputation, diplopia, ptosis, exophthalmos) [2] [4] [5] [6].

Blindness due to ischemic neuropathy secondary to orbital compression, such as apical stenosis, is exceptional [5] [6], CKD-MBD responsible for thickening and brown tumors of the base of the skull (1% - 2%) are the most frequent causes. Lesions secondary to brown orbital tumors are much rarer (1.5% to 13% CKD) and essentially ethmoidal [2] [5] [6]. Brown tumors are purely lytic lesions with poor bone formation [6]. They variably associate bone resorption and osteosclerosis, and can reach a sufficient volume and blow the cortex [2].

In our patient, the compression that caused the blindness was secondary to a reduction in the size of the optic channels by thickening of the skull base. The elevated levels of ALP and PTH, as well as the normal calcium and phosphate-mia, found in our case, have been reported by other studies [1] [8]. Indeed, hypercalcemia is intermittent, hypercalcemia and hyperphosphatemia can also be observed. However, the level of PTH did not show a correlation with clinical severity and imaging [4].

4. Conclusion

Such advanced forms of secondary hyperparathyroidism are increasingly rare. This observation underlines the importance of early detection of SHPT, in order to avoid its major complications, such as blindness, especially since current preventive and curative measures have proven their effectiveness.

Conflicts of Interest

The authors declare no conflicts of interest regarding the publication of this paper.

References

- [1] Beji, S., Rais, L., Ben Aiech, D., *et al.* (2008) Une forme historique d'hyperparathyroïdie secondaire. *La Revue de Médecine Interne*, **29**, S346. <https://doi.org/10.1016/j.revmed.2008.10.157>
- [2] Kahn, J.L. and Bourjat, P. (2005) Imagerie des atteintes faciales de l'hyper parathyroïdisme. *Journal de Radiologie*, **86**, 999-1002. [https://doi.org/10.1016/S0221-0363\(05\)81483-0](https://doi.org/10.1016/S0221-0363(05)81483-0)
- [3] Hamouda, M., Ben Dhia, N., Aloui, S., *et al.* (2011) Traitement chirurgical de l'hyperparathyroïdie secondaire chez l'insuffisant rénal chronique. *Néphrologie & Thérapeutique*, **7**, 105-110. <https://doi.org/10.1016/j.nephro.2010.10.003>
- [4] Al-Gahtany, M., Cusimano, M., Singer, W., *et al.* (2003) Brown Tumors of the Skull Base: Case Report and Review of the Literature. *Journal of Neurosurgery*, **98**, 417-420. <https://doi.org/10.3171/jns.2003.98.2.0417>
- [5] Schweitzer, V.G., Thompson, N.W. and McClatchey, K.D. (1986) Sphenoid Sinus Brown Tumor, Hypercalcemia, and Blindness: An Unusual Presentation of Primary Hyperthyroidism. *Head & Neck Surgery*, **8**, 379-386. <https://doi.org/10.1002/hed.2890080509>
- [6] Héran, F. (2010) Imagerie des masses orbitaires. *Neurochirurgie*, **56**, 89-120. <https://doi.org/10.1016/j.neuchi.2010.02.031>
- [7] Montasser, D.I., Benyahia, M., Zajjari, Y., El Allam, M. and Oualim, Z. (2011) Traitement chirurgical de l'hyperparathyroïdie secondaire chez l'hémodialysé chronique. *Néphrologie & Thérapeutique*, **7**, 314. <https://doi.org/10.1016/j.nephro.2011.07.114>
- [8] Tarrass, F., Ayad, A., Benjelloun, M., *et al.* (2006) Cauda Equina Compression Revealing Brown Tumor of the Spine in a Long-Term Hemodialysis Patient. *Joint Bone Spine*, **73**, 1422-1424. <https://doi.org/10.1016/j.jbspin.2006.01.011>
- [9] Triantafillidou, K., Zouloumis, L., Karakinaris, G., Kalimeras, E. and Iordanidis, F. (2006) Brown Tumors of the Jaws Associated with Primary or Secondary Hyperparathyroidism. A Clinical Study and Review of the Literature. *American Journal of Otolaryngology*, **27**, 281-286. <https://doi.org/10.1016/j.amjoto.2005.11.004>
- [10] Murphey, M.D., Sartoris, D., Quale, J.L., Patbria, M.N. and Martin, N.L. (1993) Musculo Skeletal Manifestations of Chronic Renal Insufficiency. *RadioGraphics*, **13**, 357-379. <https://doi.org/10.1148/radiographics.13.2.8460225>
- [11] Parrish, C.M. and O'Day, D.M. (1986) Brown Tumor of the Orbit. Case Report and Review of the Literature. *Archives of Ophthalmology*, **104**, 1199-1202. <https://doi.org/10.1001/archopht.1986.01050200105061>
- [12] Lee, D.K. and Eiferman, R.A. (2006) Ocular Calcifications in Primary Hyperthyroidism. *Archives of Ophthalmology*, **124**, 136-137. <https://doi.org/10.1001/archopht.124.1.136>
- [13] Abeysiri, P. and Sinha, A. (2006) An Unusual Pattern of Corneal Calcification in Tertiary Hyperparathyroidism. *Archives of Ophthalmology*, **124**, 138-139. <https://doi.org/10.1001/archopht.124.1.138>
- [14] Petrohelos, M., Ticoulis, D. and Diamantacos, P. (1977) Band Keratopathy with Bilateral Deafness as a Presenting Sign of Hyperparathyroidism. *British Journal of Ophthalmology*, **61**, 494-495. <https://doi.org/10.1136/bjo.61.7.494>